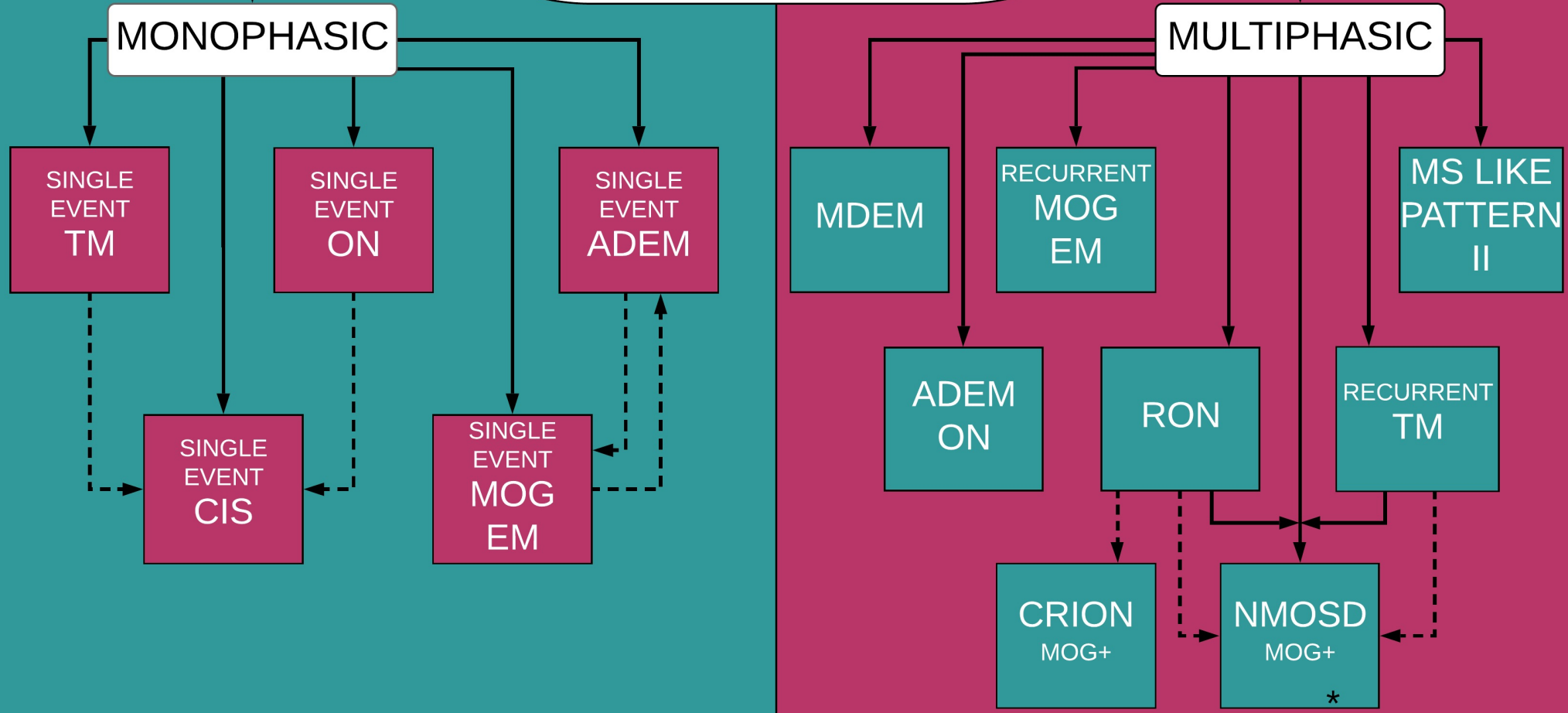


MOG Antibody Disease Diagnostic Relationships



GLOSSARY

ADEM	Acute Disseminated Encephalomyelitis
ADEM ON	Single Event ADEM Followed by recurrent ON
CIS	Clinically Isolated Syndrome of focal or multifocal demyelinating lesions without encephalopathy
CRION	Chronic Recurrent Inflammatory Optic Neuropathy
MDEM	Multiphasic Acute Disseminated Encephalomyelitis
MOG-EM	MOG Encephalomyelitis including meningo-encephalitis, encephalitis, and brainstem encephalitis all with or without Optic Neuritis
MOG+	Positive For Myelin Oligodendrocyte Glycoprotein Antibodies
MONOPHASIC	Single demyelinating event with no additional occurrences while testing MOG+
MULTIPHASIC	Multiple occurrences of demyelinating events while initially testing MOG+
MS LIKE PATTERN II	Multiple Sclerosis like symptoms (Pattern II is a rare subtype of MS)
NMOSD	Neuromyelitis Optica Spectrum Disorder
ON	Optic Neuritis
RON	Recurrent Optic Neuritis
TM	Transverse Myelitis

LEGEND

- Shows diagnosis related to MOG
- Shows possible differential diagnosis due to similar or overlapping symptoms
- Monophasic/single attack
- Multiphasic/multiple attacks
- For this diagram NMOSD is represented as MOG positive and AQP4 negative

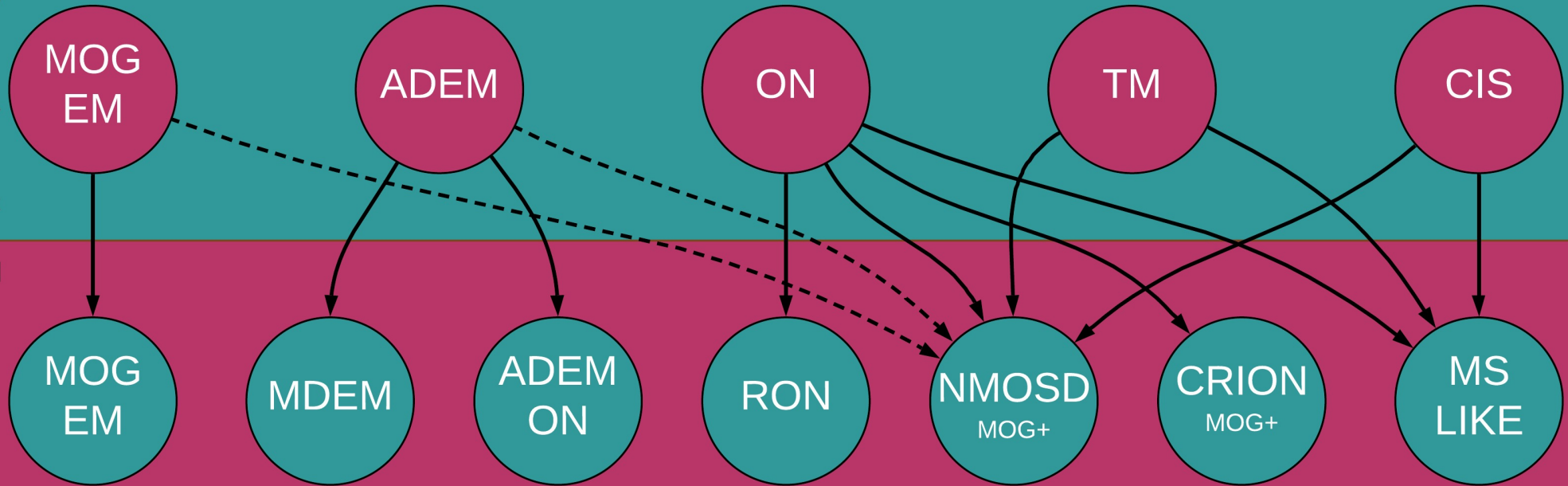
MOGMENTUM SERIES 2
BROUGHT TO YOU BY
THE MOG PROJECT
and
THE SUMAIRA FOUNDATION



MOG Antibody Disease Linked Diagnosis Progression: Monophasic to Multiphasic

MONOPHASIC





MULTIPHASIC



GLOSSARY

ADEM	Acute Disseminated Encephalomyelitis
ADEM/ON	Single Event ADEM Followed by recurrent ON
CIS	Clinically Isolated Syndrome of focal or polyfocal demyelinating lesions without encephalopathy
CRION	Chronic Recurrent Inflammatory Optic Neuropathy
MDEM	Multiphasic Acute Disseminated Encephalomyelitis
MOG-EM	MOG Encephalomyelitis including meningo-encephalitis, encephalitis, and brainstem encephalitis all with or without Optic Neuritis
MOG+	Positive For Myelin Oligodendrocyte Glycoprotein Antibodies
MONOPHASIC	Single demyelinating event with no additional occurrences while testing MOG+
MULTIPHASIC	Multiple occurrences of demyelinating events while initially testing MOG+
MS LIKE	Multiple Sclerosis like symptoms
NMOSD	Neuromyelitis Optica Spectrum Disorder
RON	Recurrent Optic Neuritis
ON	Optic Neuritis
TM	Transverse Myelitis

LEGEND

-  Directional flow of diagnosis progression
-  Differential diagnosis if NMOSD criteria is met (Possible)
-  Original diagnosis after single attack
-  New diagnosis after multiple attacks

MOGMENTUM SERIES 2
BROUGHT TO YOU BY
THE MOG PROJECT
and
THE SUMAIRA FOUNDATION

